

## ASPERGILLOSIS: A LIMITING FACTOR DURING RECOVERY OF CAPTIVE MAGELLANIC PENGUINS

Melissa O. Xavier<sup>1\*</sup>; Mauro P. Soares<sup>2</sup>; Ana Raquel M. Meinerz<sup>3</sup>; Márcia O. Nobre<sup>4</sup>; Luiza G. Osório<sup>5</sup>; Rodolfo P. da Silva Filho<sup>6</sup>; Mário Carlos A. Meireles<sup>1</sup>

<sup>1</sup>Departamento de Medicina Veterinária Preventiva, Faculdade de Veterinária, Universidade Federal de Pelotas, Pelotas, RS, Brasil; <sup>2</sup>Laboratório Regional de Diagnóstico, Faculdade de Veterinária, Universidade Federal de Pelotas, Pelotas, RS, Brasil; <sup>3</sup>Faculdade de Veterinária, Universidade Federal do Rio Grande do Sul, Porto Alegre, RS, Brasil; <sup>4</sup>Departamento de Clínicas Veterinária, Faculdade de Veterinária, Universidade Federal de Pelotas, Pelotas, RS, Brasil; <sup>5</sup>Faculdade de Veterinária, Universidade Federal de Pelotas, Pelotas, RS, Brasil; <sup>6</sup>Centro de Recuperação de Animais Marinhos de Rio Grande, Museu Oceanográfico, Fundação Universidade do Rio Grande, Rio Grande, RS, Brasil

Submitted: November 30, 2006; Returned to authors for corrections: February 02, 2007; Approved: July 18, 2007.

---

### ABSTRACT

The article describes the epidemiology, macroscopic and histological lesions as well as the isolation of *Aspergillus flavus* and *A. fumigatus* from Magellanic penguins (*Spheniscus magellanicus*) during recovery in the Center for Recovery of Marine Animals (CRAM - 32°S/52°W), over a period of two years. From January 2004 to December 2005 the Center received 52 Magellanic penguins, and 23% (12/52) died. Necropsies were performed and tissue samples were collected for histological and microbiological examination. From 12 dead animals, aspergillosis was confirmed in five animals, corresponding to 42% of the mortality. Granulomatous nodules were observed mainly on air sacs and lungs. Histologically, septate and branching hyphae, measuring 3-5 µm and PAS positive were found. Two of these cases were caused by *A. fumigatus*, two other by *A. flavus*, and in one the diagnosis was established by macroscopic lesions observed in the necropsy without sample collection for fungal isolation and identification. The five aspergillosis cases occurred in the first year of the study, when a disinfection program was not yet established in the CRAM. This paper points out the importance of aspergillosis in the rehabilitation process of captive penguins, and emphasize the necessity of an environmental disinfection on the aspergillosis prevention, mycosis that caused a high rate of mortality of the seabirds found on the Brazilian coast and admitted in the CRAM.

**Key words:** aspergillosis, rehabilitation, penguins, captivity.

---

### INTRODUCTION

Magellanic penguins (*Spheniscus magellanicus*) live on the southern coasts of South America, in the Pacific and Atlantic Oceans, in the Falkland Islands and in Tierra del Fuego (18). Usually they migrate in the direction of Argentina and Brazil to feed on fish. During this migratory route many of these birds are exposed to adverse environmental conditions and some of them are found on beaches, generally showing poor body conditions with dehydration, hypothermia, skin lesions, traumatic process or oiled and then, they are sent to rehabilitation (5-7,14,16,18).

In Brazil, there are 14 institutions, distributed in different states of the country that promote rehabilitation of marine animals (6). The unique specific center for the rehabilitation of marine fauna in Brazil, with emphasis on oiled animals is situated in the South of Brazil in the city of Rio Grande, RS (32°S/52°W). In this center, named 'Centro de Reabilitação de Animais Marinhos (CRAM), all the necessary procedures for the animals to acquire good conditions to be reintroduced in the environment are carried out (16).

During the period that penguins stay in captivity, many of them are affected by diseases that cause death hindering the

---

\*Corresponding Author. Mailing address: R: Paul Harris, 537 Areal 96077-200 Pelotas, RS - Brasil. Tel.: (53) 3275-7496. E-mail: melissa@ufpel.edu.br

process of rehabilitation and reintroduction to the environment. Among these diseases aspergillosis stands out, an opportunist mycosis caused by the *Aspergillus* genus, which affects mainly the respiratory system and is considered one of the most important causes of mortality in captive penguins (1,4,8,11,15).

Avian aspergillosis could be classified into acute or chronic disease. The acute presentation is usually a flock problem with juveniles that are exposed to high spore levels, progressing rapidly and causing death within 48 hours. In many cases it is severe and includes dyspnea, with high morbidity and mortality rates. The main route of dissemination of the fungi is through the respiratory system with only minor spread by blood circulation. The chronic presentation usually appears in individual adults that have been exposed to low spore levels but are immunosuppressed due to stress, disease, antibiotic or steroidal therapy. The bird becomes unable to effectively eliminate a normal inhalation of *Aspergillus* spores, which colonize local tissue and can cause focal and/or disseminated form of aspergillosis. The most frequent site of chronic focal form of the disease on marine avian is the trachea while the disseminated form generally starts in the lungs and air sacs and spreads to other tissues like bones, liver, spleen and kidney. The chronic presentation progresses slowly for weeks or months, with low rates of morbidity and mortality (1,10,13).

Several preventive measures are used against the disease, nevertheless in some occasions these preventive measures can not avoid outbreaks of aspergillosis. Among several preventive measures we can highlight the administration of antifungal therapy to susceptible penguins (9,16), the control of air quality with laminar flow, the use of air filters and programs for disinfection of the surroundings (1,3,10).

This report describes some epidemiologic factors of the aspergillosis in Magellanic penguins received on CRAM over a two-year period.

## MATERIALS AND METHODS

During the period of January 2004 to December 2005 the routine of recovering penguins at CRAM was attended. In this center, all admitted penguins were identified, weighted, and evaluated for the amount of oil and the hematocrit value (Ht), according to the protocol described by Ruoppolo *et al.* (16). With the aim of evaluating the clinical evolution of the recovering penguins, all birds were weighted weekly, clinically examined and blood sample was collected to determine the hematocrit level.

The preventive measure used against aspergillosis in CRAM is the administration of oral itraconazole (Sporanox® - Janssen-Cilag Farmacêutica Ltda. - São Paulo, SP) (15 mg/kg/day, during 15 days), for newly-arrived penguins with body weight less than 2.5 kg. This preventive therapy was made during the two years, and started in the arrival after the clinical examination of the birds.

Since January 2005, a disinfection program was established in the CRAM to increase the air quality, reducing airborne conidia concentration in the facilities of the captive penguins. This disinfection program consisted of cleaning daily the indoor equipments and objects with the use of a chemical agent (chlorhexidine-cetrimida - Clorexidina-Cetrimida Chemitec® - Chemitec Agro-Veterinária, São Paulo, SP).

The penguins that died were sent to necropsy to determine the cause of death. In the necropsy macroscopic alteration was evaluated and fragment of tissues were collected for histology and mycology.

Samples collected for histology were fixed in 10% buffered formalin and embedded in paraffin. Sections (3-4 µm) were stained with haematoxylin and eosin (HE), periodic acid-Schiff (PAS) and Grocott's methanamine silver (GMS).

For mycology, the samples were submitted to direct examination with KOH 20%, and to culture in triplicate in Sabouraud dextrose agar with cloranfenicol, incubated at 37°C for seven days with daily observation of the culture.

## RESULTS

During the period of study 52 Magellanic penguins, 47 juveniles and 5 adults were received. The birds had body weight ranging from 1.8 to 3.2 kg, values situated below the normal reference for the species (approximately 4 kg). A total of 18 penguins had oiled feathers and 11 had low Ht value (<35%). Over the two-year period 40 birds (77%) were recovered and 12 (23%) died. Among these dead penguins, two died with less than 24 hours after the arrival, three with less than seven days, four with approximately 20 days in captivity, two after 30 days of the arrival and one after 90 days.

The necropsy, histological and mycological examination established the aspergillosis diagnostic in 42% (5/12) of the dead animals during the two years of the study. However, all the deaths were registered in the first year, resulting in a rate of 83% of death caused by aspergillosis in 2004 and 0% in 2005. Seven other penguins died from other causes as cachexia or pododermatitis with secondary septicemia.

All the animals that had aspergillosis were juveniles and had poor body conditions, the hematocrit value was low and only one was oiled. All the deaths occurred as isolated cases, causing penguins deaths in distinct months, June, July, September and October.

Macroscopic alterations in five birds with aspergillosis were varied. Although all penguins showed lesions in the respiratory system, the acute aspergillosis presentation, characterized by miliary white-yellowish granulomatous nodules in the lung, was found in three penguins that had sudden death, and the chronic presentation, with the wall of air sacs thickened and disseminated to the other organs was observed in two penguins that had respiratory clinical signs

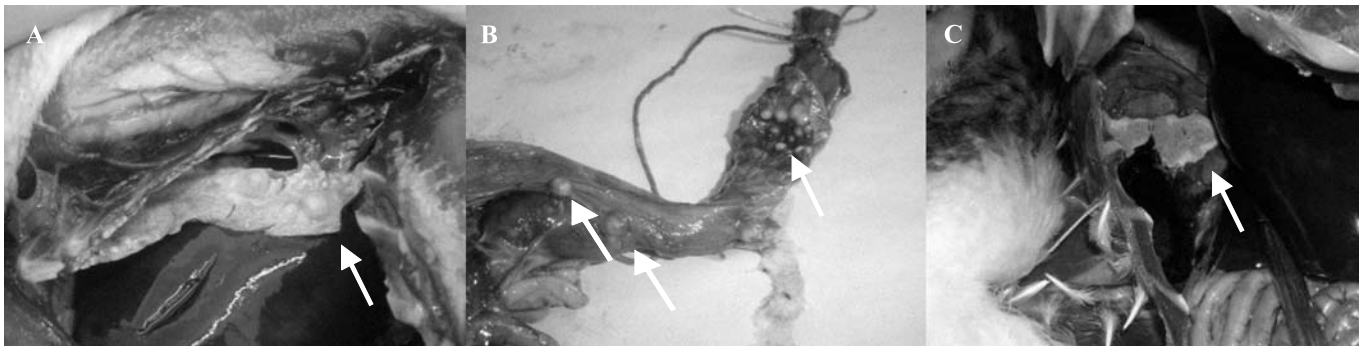
such as dyspnea and pulmonary stertors, loss of appetite and lethargy preceding the death.

The necropsy of the three penguins with the acute presentation revealed lungs with congestion and small white-yellowish nodules with 1-3 mm. Two penguins with chronic presentation (Fig. 1) presented thickened air sacs with abundant caseous and necrotic debris and grayish-green fungal colonies and nodules with 1 mm to 1 cm in the air sacs and lungs. One penguin had white-yellowish nodules with approximately 0.5 cm, disseminated throughout the thoracic cavity and externally in the esophagus. Another penguin showed also nodules and fungal colonies in the kidneys and liver and the syrinx had a nodule measuring approximately 7 cm, with caseous material in the center and recovered with whitish plaques. One bird with a chronic presentation did not have material sent to the fungal culture, but the macroscopic and histological lesions were typical of aspergillosis.

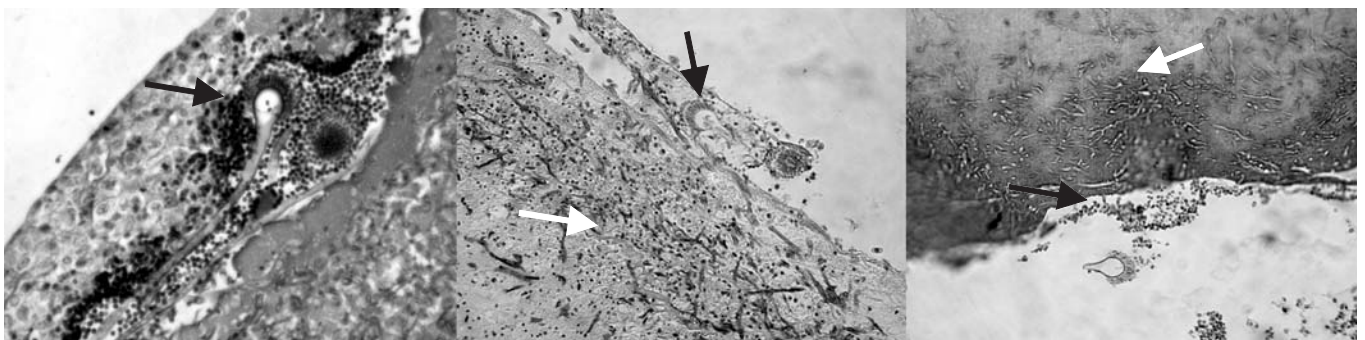
Histologically, penguins with acute presentation had lungs with necrotic areas with septate and branching hyphae, measuring 3-5  $\mu$ m and PAS positive growing in a radial pattern

rimmed by cell debris, hemorrhage and infiltrates of heterophilic, mononuclear and multinuclear cells. In the chronic presentation it was observed in the lungs, liver, kidneys and syrinx a necrotic foci surrounded by macrophages, heterophils and giant cells, sometimes within a fibrous tissue proliferation at the periphery. The air sacs presented thickness and abundant caseous material. Septate and branching hyphae, giant cells, mononuclear and multinuclear cells and the characteristic conidial head of *Aspergillus* were also present (Fig. 2).

Direct examination with KOH of the samples in mycology revealed septate and branching hyphae in tissues and conidial heads in air sacs. Culture allowed to identify the etiologic agent as *A. fumigatus* in two cases and as *A. flavus* in two other animals, represented, respectively, by grayish turquoise colonies with rapidly growing and uniseriate phialides over upper half to two-thirds of the pyriform vesicle, and by yellow-green colonies with rough-walled stipes, spherical vesicles and metulae covering three quarters of the entire surface of the vesicle.



**Figure 1.** Macroscopic lesions of aspergillosis in Magellanic penguins: (A) air sacs thickened with abundant caseous and nodules; (B) nodules white-yellowish externally in esophagus; (C) fungal colonies in the air sacs.



**Figure 2.** Conidial heads of *Aspergillus* spp. and septate and branching hyphae, in air sacs of Magellanic penguins at histological examination with HE (100X).

## DISCUSSION

The importance of aspergillosis in different species of captive penguins is reported since the 40s, causing mortality rates between 50-100% in marine birds in different regions of the world (2,4,9,11,12,17). In our work the high frequency of aspergillosis was reaffirmed and it corresponded to approximately 50% of the mortality in recovering penguins. This numbers can be explained by the difficulty in prophylaxis and early diagnosis of this disease and consequent inefficacious treatment, which results in death of the majority of the affected birds.

The acute presentation of aspergillosis was observed in 60% of the Magellanic penguins affected, differing from the values found by Hocken (9), who observed only 14% of acute presentation in *Eudyptula m. minor* species. However the work of Hocken was carried out with wild penguins that had only nutritional stress as an immunosuppressant factor, while the recovering penguins at CRAM went through stress factors like: manipulation, transport, habitat changing, among others, increasing even further the immunosuppression which predisposes to this mycosis with more serious injuries and more rapidly (9).

The corporal debilitation, characterized by malnutrition, dehydration and hypothermia, captivity stress, antibiotic or steroidal therapy and the oil toxicity are factors that predispose recovering penguins to aspergillosis (1,17). In spite of the oil being considered an important factor to induce a serious immunosuppression, in our work this factor was not characterized as an important factor to predispose the penguins to aspergillosis, because from 18 oiled penguins treated during this period only one had aspergillosis.

Young birds have immature immune system that increases the avian susceptibility to aspergillosis (1,4). In our cases all penguins that died with this mycosis were juveniles, but with our results we can not affirm that this category is more susceptible, because in this study juvenile penguins represented 90% of the total birds received in CRAM.

In spite of *A. fumigatus* being the fungal specie more frequently involved on penguins aspergillosis (2,11), in our work, this specie was found at the same frequency as *A. flavus*, that is also considered a pathogenic species associated to clinical cases of aspergillosis in marine and domestic birds (2,3). Therefore it has to be consider that the values obtained could be different if the number of animals was increased.

The aspergillosis in captive penguins does not have a constant annual prevalence, occurring frequently as outbreaks that cause high mortality rates in some years and in others the mortality tend to nullity (4). In CRAM the occurrence of aspergillosis was not an outbreak, but occurred as isolated cases. This fact is justified by the opportunistic characteristic of this mycosis, that usually occur when there is host immunosuppression associated or not with the increase inhalation of spores (1,3,15).

The mortality decrease in the second year of the study was attributed to the establishment of a disinfection program in CRAM. The cleaning and disinfection program is the basis of a good sanitary program because it decreases the quantity of spores in the environment and increases the air quality (1,3,10).

## CONCLUSION

This work shows that the aspergillosis is an important disease that causes mortality during the recovering process of rehabilitation of penguins in captivity. To the best of our knowledge this is the first report of epidemiology of aspergillosis in penguins found on Brazilian beaches and sent to CRAM, showing high levels of mortality, and emphasize the necessity of an environmental disinfection on this mycosis prevention.

## RESUMO

### **Aspergilose: Um fator limitante na reabilitação de pingüins-de-Magalhães**

O trabalho descreve fatores epidemiológicos, achados de necropsia, histológicos e o isolamento de *Aspergillus flavus* e *A. fumigatus* em pingüins-de-Magalhães (*Spheniscus magellanicus*) em reabilitação no Centro de Recuperação de Animais Marinhos (CRAM - 32°S/52°W), durante um período de dois anos. De janeiro de 2004 a dezembro de 2005 foram recebidos no Centro, 52 pingüins-de-Magalhães, dos quais 23% (12/52) morreram. Esses animais foram necropsiados e amostras de tecidos foram coletadas para exame histológico e microbiológico. De 12 animais necropsiados, aspergilose foi diagnosticada em 42% (5/12). Granulomas foram observados principalmente em sacos aéreos e pulmões e hifas septadas, hialinas e dicotômicas em ângulo agudo foram encontradas na histologia. Dois casos foram ocasionados por *A. fumigatus*, outros dois por *A. flavus* e em um caso o diagnóstico foi estabelecido pelas lesões macroscópicas observadas na necropsia, sem a coleta de amostra para isolamento e identificação fúngica. Os cinco casos da micose ocorreram no primeiro ano, período em que não havia um programa de desinfecção no Centro. Este trabalho ressalta a importância da aspergilose interferindo no processo de reabilitação de pingüins em cativeiro no CRAM, e enfatiza a necessidade da desinfecção ambiental na prevenção da micose, doença que causa uma alta taxa de mortalidade de aves marinhas encontradas na costa brasileira e encaminhadas ao CRAM.

**Palavras-chave:** aspergilose, reabilitação, pingüins, cativeiro

## REFERENCES

1. Abundis-Santamaria, E. (2005). Aspergillosis in birds of prey, 2003. Available at: <http://www.aspergillus.man.ac.uk>. Accessed 23 March 2005.

2. Ainsworth, G.C.; Rewell, R.E. (1949). The incidence of aspergillosis in captive wild birds. *J. Comp. Pathol. Ther.*, 59, 213-224.
3. Andreatti Filho, R.L. (2000). Enfermidades micóticas, *In: Berchieri Júnior, A.; Macari, M. Doenças das aves*. Campinas: FACTA - Fundação APINCO de Ciência e Tecnologia Avícolas, p.369-375.
4. Flach, E.J.; Stevenson, M.F.; Henderson, G.M. (1990). Aspergillosis in gentoo penguins (*Pygoscelis papua*) at Edinburgh Zoo, 1964-1988. *Vet. Rec.*, 126(4), 81-85.
5. Fowler, G.S.; Fowler, M.E. Order Sphenisciformes (Penguins). (2001). *In: Fowler, M.E.; Cubas, Z.S. Biology, medicine and surgery of South American wild animals*. Iowa State University Press, USA, p.53-64.
6. García-Borboroglu, P.; Boersma, P.D.; Ruoppolo, V.; Reyes, L.; Rebstock, G.A.; Griot, K.; Heredia, S.R.; Adornes, A.C.; Silva, R.P. (2006). Chronic oil pollution harms Magellanic penguins in the Southwest Atlantic. *Mar. Pollut. Bull.*, 52, 193-198.
7. Gandini, P.; Boersma, P.D.; Frere, E.; Gandini, M.; Holik, T.; Lichtschein, V. (1994). Magellanic penguin (*Spheniscus magellanicus*) affected by chronic petroleum pollution along coast of Chubut, Argentina. *The Auk.*, 111(1) 20-27.
8. Graczyk, T.K.; Cranfield, M.R. (1995). Maternal transfer of anti-*Aspergillus* spp. Immunoglobulins in African Black-footed Penguins (*Spheniscus demersus*). *J. Wildl. Dis.*, 31(4), 545-549.
9. Hocken, A.G. (2000). Cause of death in blue penguins (*Eudyptula m. minor*) in North Otago, New Zealand. *N. Z. J. Zool.*, 27, 305-309.
10. Kearns, K.S.; Loudis B. (2003). Avian aspergillosis. *In: Recent Advances in Avian Infectious Diseases, Int. Vet. Inf. Serv.*, Ithaca NY.
11. Khan, Z.U.; Pal, M.; Paliwal, D.K.; Damodaram, V.N. (1977). Aspergillosis in imported penguins. *Sabouraudia*, 15, 43-45.
12. Kittle, D. (2004). Zoo without penguins after fatal 02 illness, 06/02/2003. Available at: <http://www.potterparkzoo.org>. Accessed 23 March 2004.
13. Martínéz, R.R.; Cerecero, J.; Cervantes, J. (2000). Brote de aspergilosis em gaviotas. *Vet. Méx.*, 31(3), 259-260.
14. Petry, M.V.; Fonseca, V.S.S. (2002). Effects of human activities in the marine environment on seabirds along the coast of Rio Grande do Sul, Brazil. *Ornitol. Neotrop.*, 13, 137-142.
15. Redig, P.T. (1993). General Infectious Diseases - Avian Aspergillosis. *In: Fowler, M.E. Zoo & Wild Animal Medicine - current therapy 3*. Denver, Colorado, p.178-181.
16. Ruoppolo V.; Adornes, A.C.; Nascimento, A.C.; Silva-Filho, R.P. (2004). Reabilitação de pingüins afetados por petróleo. *Clín. Vet.*, 51, 78-83.
17. Russel, M.; Holcomb, J.; Berkner, A. (2003). *30-Years of Oiled Wildlife Responses Statistics*. Proceedings of the 7<sup>th</sup> International Effects of Oil and Wildlife Conference Hamburg, Germany, p.1-18.
18. Willians, T.D. (1995). *The Penguins, Spheniscidae*, Oxford University Press.